



**PRESENTING CLINICAL SIGNS**

**DATE** History: Previously diagnosed with stage B1 degenerative valve disease and mild PH in July 2021. Doing well. No current cardiac medications. Radiographs in July 2022 showed mild cardiomegaly.

12/22/22

**ECHOCARDIOGRAPHIC FINDINGS**

2D, M-mode, and Doppler study.

**PERFORMED BY:**

Jenna Walsh, CVT

**INTERPRETED BY**

Keith Blass, DVM,  
MS, DACVIM  
(Cardiology)

Left atrial size is normal. The mitral valve leaflets are mildly thickened and exhibit mild systolic prolapse. A mild jet of mitral regurgitation is present. Left ventricular dimensions are normal. Left ventricular systolic function is normal. The aorta and aortic valve are normal. Right atrial and right ventricular dimensions are normal. The tricuspid valve leaflets are mildly thickened, and a mild to moderate jet of tricuspid regurgitation is present. TR velocity is consistent with the presence of mild pulmonary hypertension (PG 43 mmHg). The pulmonary artery and pulmonic valve are normal. No shunting lesions are visualized. No pericardial effusion or cardiac masses are seen.

**PATIENT**

Mushu Dappletini  
Scofield

LA - 22.5 mm  
LVIDd - 22.4 mm  
LVIDs - 13.1 mm  
FS - 41.5%  
RA - 13.3 mm  
LVOT - 1.00 m/s  
RVOT - 0.60 m/s  
TR - 3.28 m/s

**SPECIES**

Canine

**ASSESSMENT/RECOMMENDATIONS**

Degenerative mitral and tricuspid valve disease  
Pulmonary hypertension

**BREED**

Chihuahua Mix

This examination demonstrates no progression of Mushu's valvular diseases or pulmonary hypertension over the past year and a half. As such, her diseases still appear to be well-compensated, and Mushu's current risk for the development of clinical signs secondary to them still appears to be low.

**SEX**

No therapy is recommended at this stage of Mushu's valvular diseases or pulmonary hypertension.

**FS**

A recheck echocardiogram is recommended in ~6 months to monitor for disease progression.

**AGE**

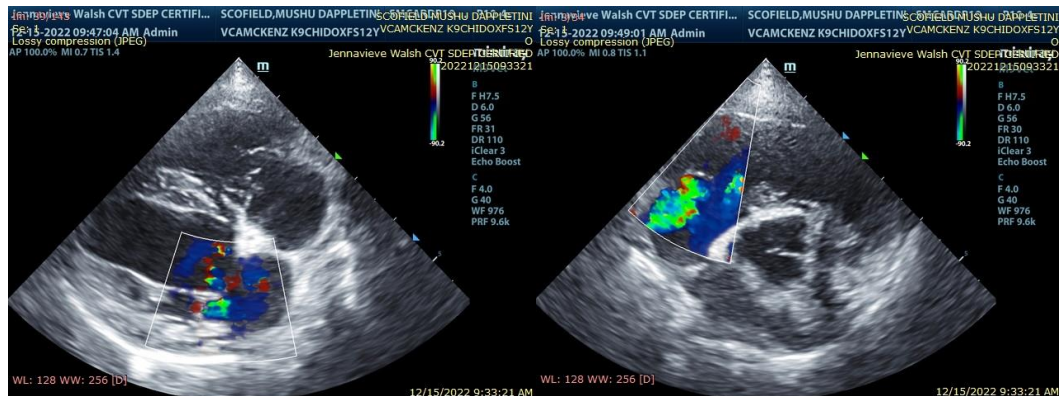
12 y

**WEIGHT**

10.12 lb

**HOSPITAL NAME**

VCA McKenzie AH



**REFERRING VET**

Dr. Fricke

The information and recommendations provided are based on the images presented by the



**DATE** referring veterinarian. No evaluation can be communicated regarding pathology that was not visible in the image/video clips provided.

12/22/22 Thank you for this referral. If the clinical or image interpretation does not parallel your findings or if I can be of any further assistance please contact me.

**PERFORMED BY:** Keith Blass, DVM, MS, DACVIM (Cardiology)  
KeithBlass@gmail.com  
Jenna Walsh, CVT 631-804-5754

**INTERPRETED BY**  
Keith Blass, DVM,  
MS, DACVIM  
(Cardiology)

**PATIENT**  
Mushu Dappletini  
Scofield

**SPECIES**  
Canine

**BREED**  
Chihuahua Mix

**SEX**  
FS

**AGE**  
12 y

**WEIGHT**  
10.12 lb

**HOSPITAL NAME**  
VCA McKenzie AH

**REFERRING VET**  
Dr. Fricke